

DIAGNOSTIC UTILITY OF CELL BLOCKS IN THYROID ASPIRATESZarika Ahmed¹, Pranita Medhi², Debojit Das³**HOW TO CITE THIS ARTICLE:**

Zarika Ahmed, Pranita Medhi, Debojit Das. "Diagnostic Utility of Cell Blocks in Thyroid Aspirates". Journal of Evolution of Medical and Dental Sciences 2015; Vol. 4, Issue 76, September 21; Page: 13221-13232, DOI: 10.14260/jemds/2015/1902

ABSTRACT: BACKGROUND: Thyroid swellings are a common clinical presentation. The distribution of benign lesions from malignant lesions cannot be made by clinical judgment. The pathological lesions need morphological workup, Fine Needle Aspirations (FNA) being one of the cornerstones. Its limitations are sample inadequacy, low cytomorphologic details and architectural insights with overlapping of cytological features. Cell block is a diagnostic method where material for morphologic evaluation is well recognized as it increases cellular yield, thus improves diagnostic accuracy. It provides excellent cytomorphologic details in concert with architectural insight with much more diagnostic efficacy, thus obviates repeat FNA. **AIMS:** To analyze the diagnostic utility of cell blocks on thyroid aspirates by taking the histopathological findings as the gold standard and statistically analyzed for diagnostic efficacy of cell block. **MATERIALS AND METHOD:** The study design was hospital based cross-sectional study. Ninety FNAC samples were taken and cell block was prepared using Tissue Thromboplastic method. Cell Block findings were analyzed by looking at the arrangement of follicular cells size, acini, nuclear cytoplasmic characteristics, colloid, stroma, inflammatory cells, malignant cells, psammoma bodies, haemorrhage, necrosis, calcification, fibrosis, amyloid or any other relevant findings. **RESULTS:** Out of the 90 cases, 69 cases (76.67%) were diagnosed as Non neoplastic lesions and 21cases (23.33%) as Neoplastic. Of the Non-neoplastic cases, colloid goiter was the commonest, (64.44%). Among the Neoplastic lesions Follicular adenoma was the commonest (11.11%). Histopathologically, out of the 47 cases, Non-neoplastic lesions were 32 cases (68.09%) and neoplastic lesions 15 cases (31.91%). Colloid goiter was the commonest thyroid lesion (53.19%). In Neoplastic lesions Follicular adenoma cases was the commonest (21.28%). There was 0 False Negative case and 2 cases of False Positive in our series. **CONCLUSION:** Cell block technique showed to be highly effective with high sensitivity and specificity and could be utilized as a cost effective diagnostic tool in the armamentarium of diagnostic work up in the patients with thyroid lesions.

KEYWORDS: Cell block, FNAC, Thyroid aspirates.

INTRODUCTION: Thyroid diseases are the most common endocrine disorders worldwide. It is estimated that 42 million people in India suffer from thyroid diseases.^[1]

Diseases of thyroid gland are due to inflammatory, hyperplastic and neoplastic conditions with varied presentations ranging from diffuse thyroid enlargement to a solitary nodule or multi nodular enlargement and patient may be in euthyroid, hypothyroid or hyperthyroid states.

Proper diagnostic procedures are necessary to determine the type of lesion which will guide the clinician in planning out a prompt line a treatment. It is preferred to operate only those patients, thereby avoiding unnecessary surgery, possible nerve injury (Recurrent laryngeal nerve), hypoparathyroidism and thyroid hormone dependence in patients with benign thyroid nodule. FNAC is taken as one of the cornerstone in the diagnoses but has some limitations which can be taken care

ORIGINAL ARTICLE

of by preparation of cell block thus providing better accuracy in diagnosis and benefits to our patients. The value of cell block as complementary diagnostic material for morphologic evaluation is well recognized. Cell block provides excellent cytomorphologic details in concert with architectural insight with much more diagnostic efficacy, thus obviates repeat FNAC.^[2-4]

However, the sole diagnostic reliability remains in the histopathological diagnosis. Thus, looking into the feasibility of cell block study, the present study has been undertaken in the cytology section of Department of Pathology, Assam Medical College & Hospital, Dibrugarh, with the aims and objectives to evaluate the diagnostic utility of cell block technique in thyroid needle aspirates and to analyze if there is any difference in sensitivity and specificity of cell block amongst distinct entities of thyroid lesions.

MATERIALS & METHOD: This is a prospective, hospital based cross sectional study with approval from the Institutional Ethics Committee.

A total of Ninety FNAs were performed from June 2013 to May 2014. Material from thyroid lesions was aspirated for conventional smears and cell block preparation simultaneously. Minimum of two needle passes were made. Two slides were immediately fixed in alcohol for Papanicolaou (Pap) staining, and two were air-dried for May Grunwald Geimsa (MGG) staining. Samples collected for the cell block were either from an additional needle aspiration and/or remained needle rinse.

For Cell Block Preparation, conventional Plasma- Thromboplastin method was used where the Principle of forming cell clot using thromboplastin and calcium ions is utilized.^[5]

To prepare the cell block, aspirate is spinned in a centrifuge for 10 minutes at 1500 G and the Cell pellet formed is separated from the supernatant. Pellet is resuspended in 3 drops of plasma, then 3 drops of thromboplastin is added, mixed gently, followed by 3 drops of Calcium Chloride. It is allowed to stand undisturbed for 15-20 minutes. Then 5-8ml 10% buffered formalin is added and allowed to fix. It is placed in a labeled tissue cassette and is processed as per the standard protocol in the histopathological section. Cell Block findings were analyzed by looking at the arrangement of follicular cells size and shape of acini/follicular cell, nuclear and cytoplasmic characteristics of follicular cells, colloid content and its characteristics, stroma, inflammatory cells/infiltration by malignant cells, psammoma bodies, haemorrhage, necrosis, calcification, fibrosis, amyloid or any other relevant findings. For adequacy/reporting and diagnosis, Bethesda criteria were followed. Histological diagnosis was considered the gold standard for evaluation of sensitivity and specificity of FNAC and cell block technique and thus evaluating and comparing their diagnostic utility. Statistical analysis of the diagnostic utility of cell block was evaluated taking into account sensitivity, specificity, Positive predictive value, negative predictive value and accuracy where confidence interval was 95% allowing 5% error.

RESULTS AND OBSERVATIONS: Fine needle aspiration cytology was carried out on 90 patients of both sexes and all age groups, presenting with either solitary thyroid nodule/multi-nodular/diffuse thyroid enlargement. On an average 2-3 passes were given. Ultrasound-guided FNAC were performed where ever indicated in all these cases FNAC slide correlation and cell blocks were studied. However, histopathological correlation could be obtained in only 47 cases (Out of 90). Thus, diagnostic efficacy of cell block taking Histopathology as the gold standard were considered based on 47 cases which could be histologically followed up.

ORIGINAL ARTICLE

AGE GROUPS (in years)	NUMBER (n)	PERCENTAGE (%)
0—10	1	1.11
11—20	7	7.78
21—30	17	18.89
31—40	31	34.44
41—50	23	25.56
51—60	9	10.00
61—70	2	2.22
≥ 71 & above	0	0.00
TOTAL	90	100.00

TABLE 1: AGE DISTRIBUTION

The majority patients were into the age group between 31–40 years. The youngest patient was 5½ year old and the oldest was 62 years old [Table-1].

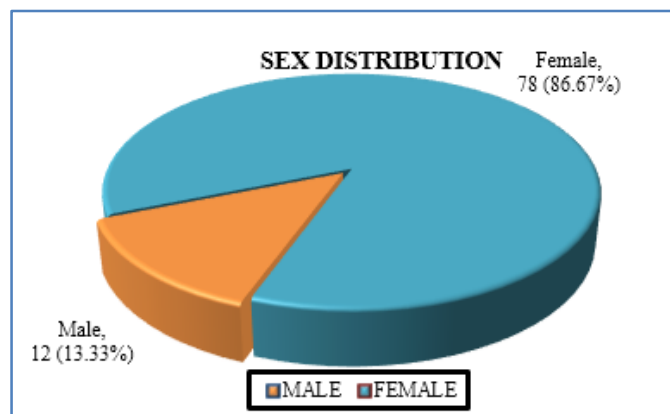


FIG. 1

In our study, there was a female preponderance associated with thyroid lesions compared to males with the male to female ratio 1: 6.5. [Fig-1]

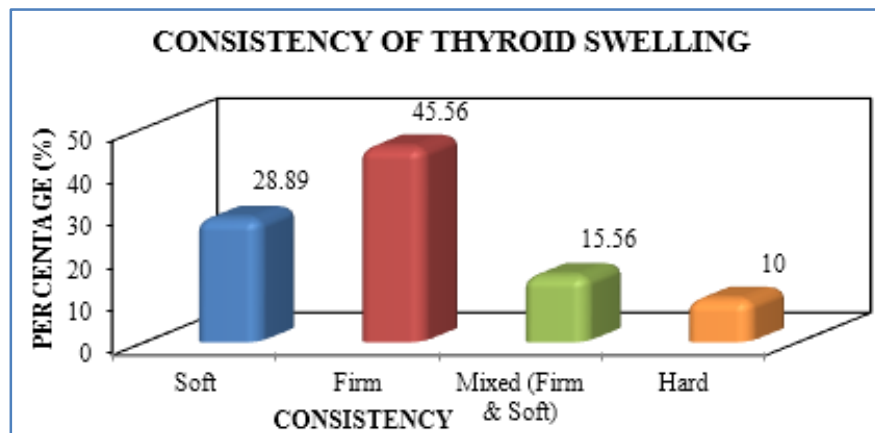


FIG. 2

ORIGINAL ARTICLE

Clinically, consistency of thyroid swelling was soft in 26 (28.89%) cases each, firm in 41 (45.56%), mixed in 14 (15.56%) cases and hard in 9 (10.00%) cases. [FIG-2]

According to the type of lesion, it was found that solitary nodule was in 48 (53.33%) cases followed by multi nodular 29(32.22%) cases and diffuses 13 (14.44%) cases. [FIG-3].

FIG. 3: TYPE OF LESION

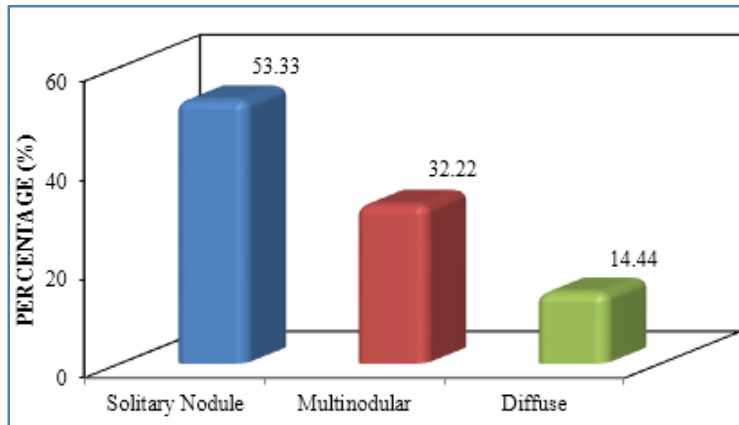


FIG. 3

DURATION (in months)	NUMBER (n)	PERCENTAGE (%)
<6	7	7.78
6—12	52	57.78
13—18	9	10.00
17—24	16	17.78
>24	6	6.67
TOTAL	90	100.00

TABLE 2: DURATION OF SYMPTOM

In our study, duration of symptoms was mostly noted between 6—12 months which is 52 (57.78%) cases. [Table-2]

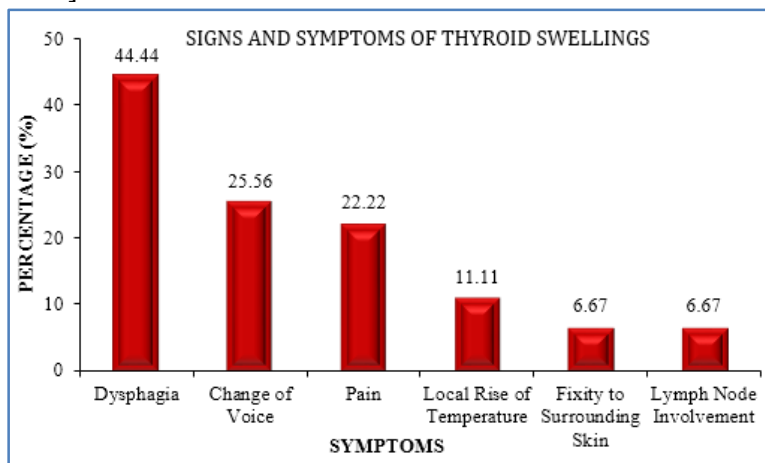


FIG. 4

ORIGINAL ARTICLE

The major presenting symptoms in our study were dysphagia which was 40(44.44%) cases followed by change of voice which was 23(25.56%) cases [FIGURE-4].

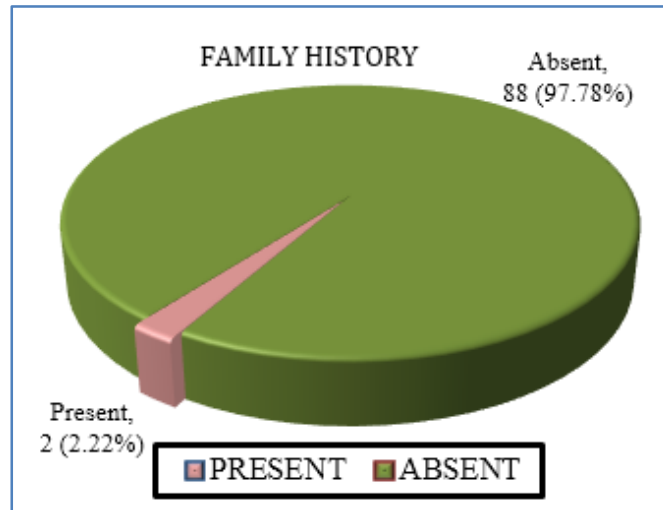


FIG. 5

In our study, only 2 (2.22%) case had a positive family history [FIGURE-5].

FNAC DIAGNOSIS	NUMBER (n)	PERCENTAGE (%)
Non Neoplastic (NN)	75	83.33
Neoplastic (N)	13	14.44
Non Diagnostic (ND)	2	2.22
TOTAL	90	100.00

TABLE 3: DISTRIBUTION OF CASES AS PER FNAC DIAGNOSIS

Distribution of Non-neoplastic cases as per FNAC diagnosis in our study was 75 (83.33%) cases while Neo plastic cases were 13 (14.44%) cases and the cases in the Non-diagnostic category was found to be 2 (2.22%) cases [Table-3]

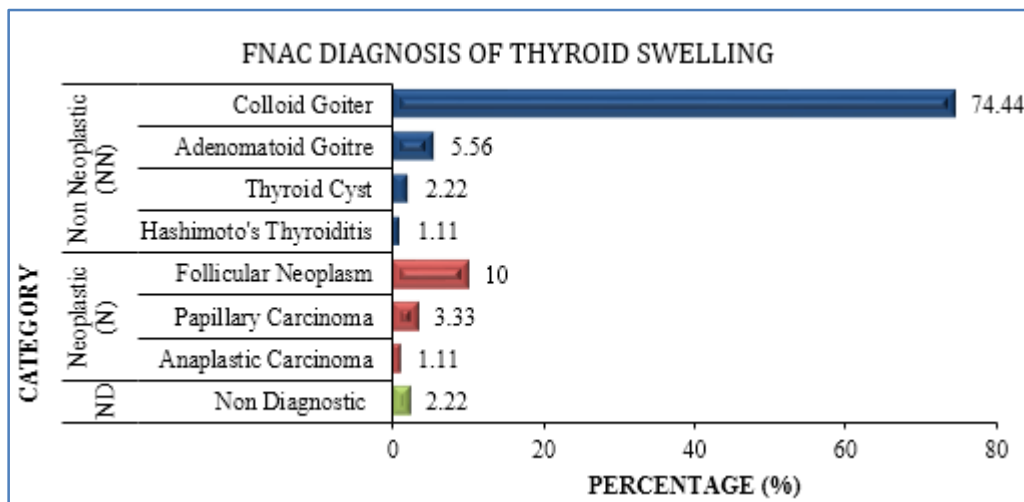


FIG. 6

ORIGINAL ARTICLE

FNAC diagnosis of Non-neoplastic lesions were 75(83.33%) cases of which colloid goiter were 67(74.44%) cases, adenomatoid goiter 5(5.56%) case, thyroid cyst 2(2.22%) cases and Hashimoto's thyroiditis 1(1.11%) case. The Neoplastic cases were 13(14.44%) cases. They were Follicular neoplasm 9(10.00%), papillary carcinoma 3(3.33%) and anaplastic carcinoma 1(1.11%) case. The Non -diagnostic cases were 2(2.22%) cases [FIGURE-6]

CELL BLOCK DIAGNOSIS	NUMBER (n)	PERCENTAGE (%)
Non Neoplastic (NN)	69	76.67
Neoplastic (N)	21	23.33
Non Diagnostic (ND)	0	0.00
TOTAL	90	100.00

TABLE 4: DISTRIBUTION OF CASES AS PER CELL BLOCK DIAGNOSIS

In our study, Distribution of Non-neoplastic cases as per cell block diagnosis was 69 (76.67%) cases while Neo plastic cases were 21(23.33%) cases [Table-4].

CATEGORY	DIAGNOSIS	NUMBER (n)	PERCENTAGE (%)
Non Neoplastic (NN)	Colloid Goiter	58	64.44
	AdenomatoidGoitre	6	6.67
	Multinodular Goiter	1	1.11
	Thyroid Cyst	3	3.33
	Hashimoto's Thyroiditis	1	1.11
Neoplastic (N)	Follicular Adenoma	10	11.11
	Follicular Neoplasm	5	5.56
	Papillary Carcinoma	4	4.44
	Medullary Carcinoma	1	1.11
	Anaplastic Carcinoma	1	1.11
Non Diagnostic (ND)		0	0.00
TOTAL		90	100.00

TABLE 5: CELL BLOCK DIAGNOSIS OF THYROID SWELLING

In our study, by cell block diagnosis, the Non-neoplastic cases were 58(64.44%) of colloid goiter, adenomatous goiter 6(6.67%) cases, multi nodular goiter 1(1.11%) case, thyroid cyst 3(3.33%) cases and Hashimoto's thyroiditis 1(1.11%) case. The Neoplastic cases were Follicular adenoma 10(11.11%) cases, Follicular neoplasm 5(5.56%) cases, papillary carcinoma 4(4.44%), medullary carcinoma 1(1.11%) case and anaplastic carcinoma 1(1.11%) case.[Table-5]

	FNAC		CELL BLOCK DIAGNOSIS	
	n	%	n	%
Non Neoplastic (NN)	75	83.33	69	76.67
Neoplastic (N)	13	14.44	21	23.33
Non Diagnostic (ND)	2	2.22	0	0.00
TOTAL	90	100.00	90	100.00

TABLE 6: COMPARISON BETWEEN FNAC AND CELL BLOCK DIAGNOSIS

ORIGINAL ARTICLE

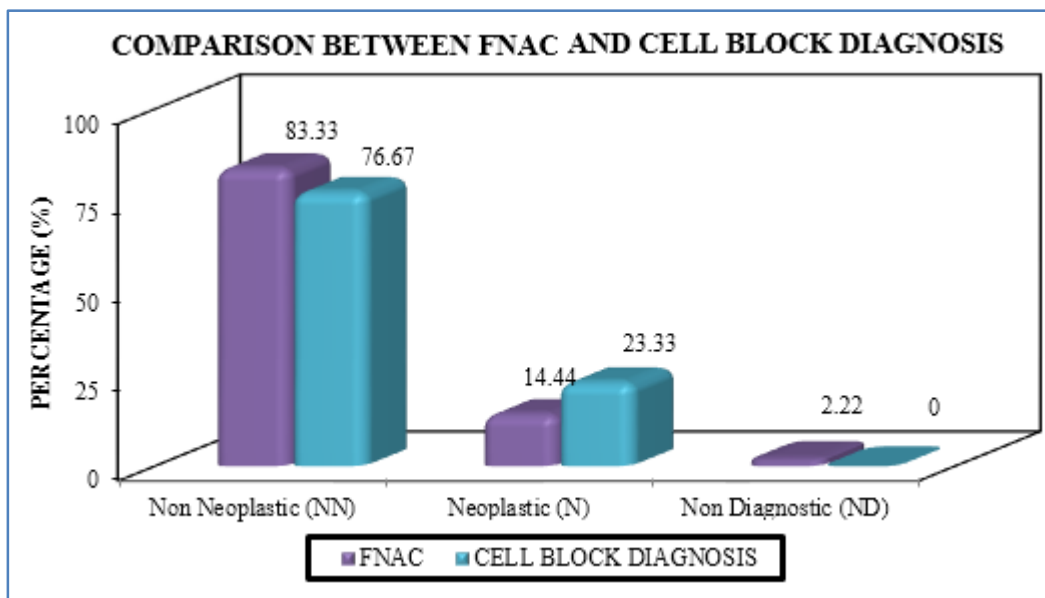


FIG. 7

HISTOPATHOLOGICAL DIAGNOSIS	NUMBER (n)	PERCENTAGE (%)
Non Neoplastic (NN)	32	68.09
Neoplastic (N)	15	31.91
Non Diagnostic (ND)	0	0.00
TOTAL	47	100.00

TABLE 7: DISTRIBUTION OF CASES AS PER HISTOPATHOLOGICAL DIAGNOSIS

In our study, as per histopathological diagnosis, distribution of Non-neoplastic cases was 32(68.09%) cases while Neo plastic cases were 15(31.91%) cases out of a total of 47 cases. [TABLE-7]

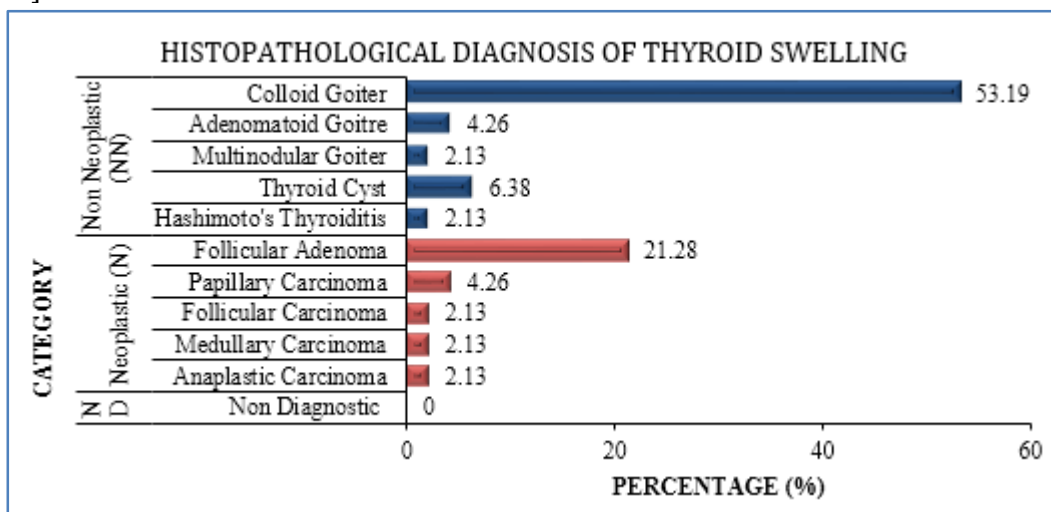


FIG. 8

ORIGINAL ARTICLE

Histologically benign lesion were 42 cases of which colloid goiter were 25 (53.19%) cases, adenomatous goiter 2 (4.26%) cases, multi nodular goiter 1 (2.13%) case, follicular adenoma 10 (21.28%), thyroid cyst 3 (6.38%) cases and Hashimoto's thyroiditis 1 (2.13%) case. The malignant cases were papillary carcinoma 2 (4.26%), follicular carcinoma 1 (2.13%), medullary carcinoma 1 (2.13%) case and anaplastic carcinoma 1 (2.13%) case. [FIGURE-8]

	CELL BLOCK DIAGNOSIS		HISTO-PATHOLOGICAL DIAGNOSIS	
	n	%	n	%
Non Neoplastic (NN)	30	63.29	32	68.09
Neoplastic (N)	17	36.71	15	31.91
Non Diagnostic (ND)	0	0.00	0	0.00
TOTAL	47	100.00	47	100.00

TABLE 8: COMPARISON BETWEEN CELL BLOCK DIAGNOSIS AND HISTOPATHOLOGICAL DIAGNOSIS

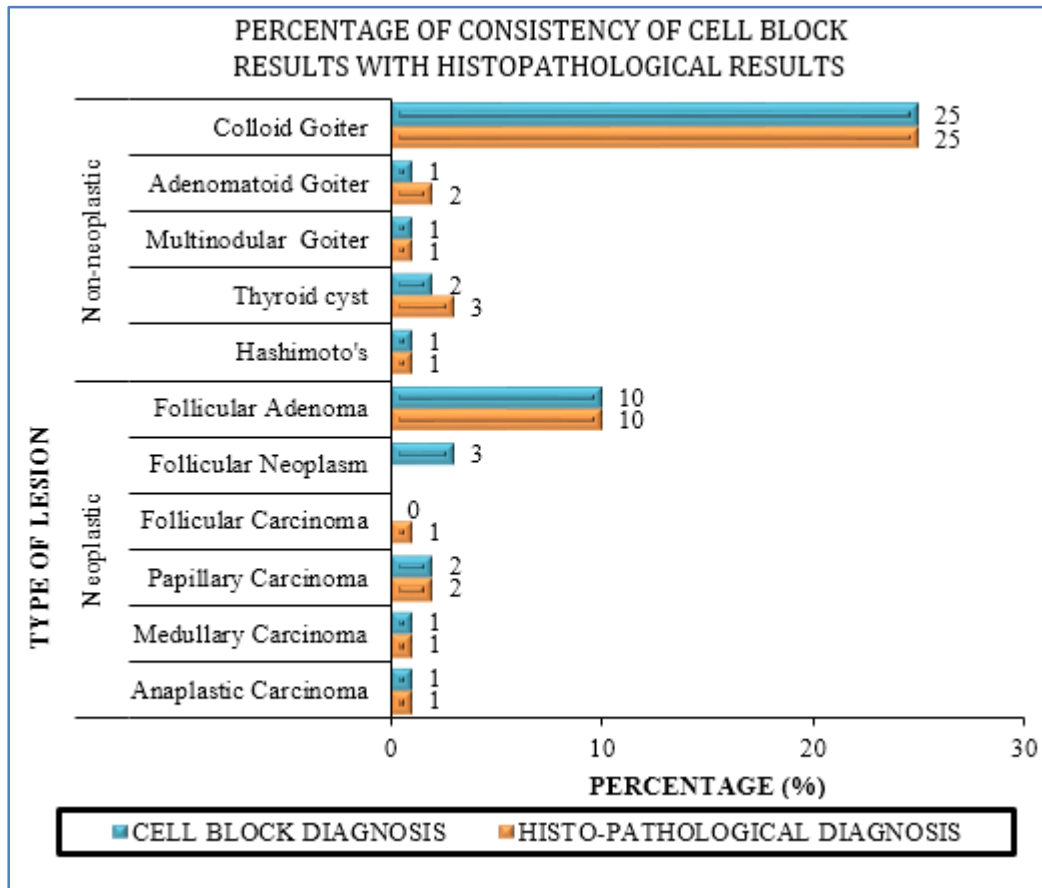


FIG. 9

ORIGINAL ARTICLE

TYPE OF TUMOUR	TOTAL CASES (HPE)	CELL BLOCK	PERCENTAGE OF CONSISTENCY
Non Neoplastic	32	30	93.75
Neoplastic	15	17	88.23

TABLE 9: PERCENTAGE OF CONSISTENCY

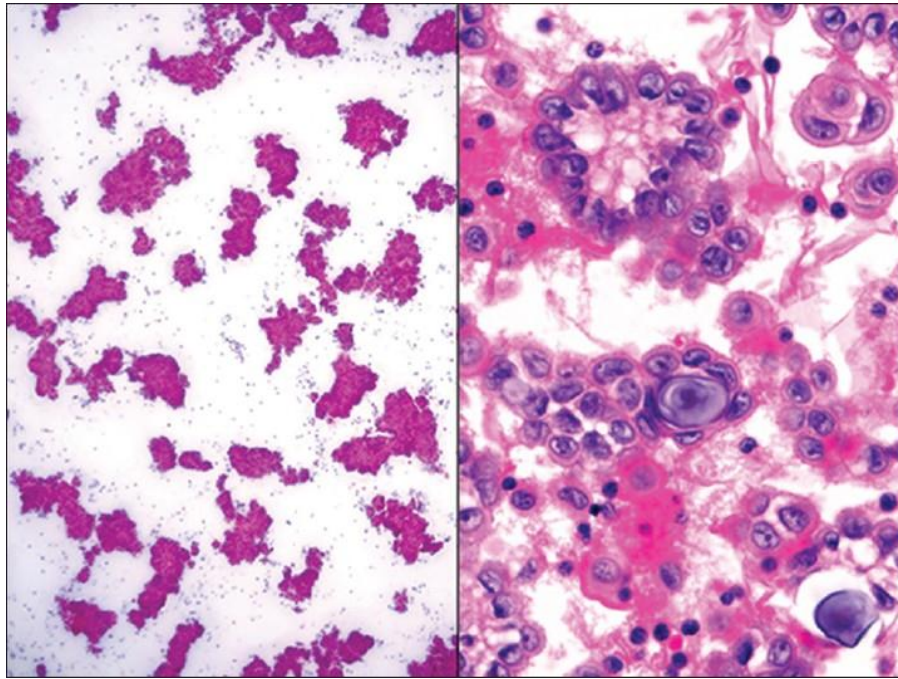


FIG. 10

Sensitivity of the present study (Cell Block Cytology) was 93.75%, specificity was 93.75%, Positive Predictive value 88.23%, Negative Predictive value 100% and Accuracy 95 which were comparable to other studies e.g. Nathan et al^[6]86.4% (n = 331), Leung and Bedard,^[7] 86% Wojcik and Selvagi,^[8] 84% (n = 125), Axe et al.,^[9] 73% (n = 22) and Kern and Haber,^[10] 60% (n = 393).

The diagnostic accuracy was found to be 95.74%. This study correlates with the study of Basnet et al.,^[11] where diagnostic accuracy was 95.91% and also with the study of Rajib et al.,^[12] who did a study on Cell blocks on thyroid cytology where diagnostic accuracy was found to be 95.7%.

In our series, there was no case of false negative (FN). Cell Block was instrumental in improving the overall diagnosis and reducing the false negative cases that were reported by FNAC. A study by Nathan et al.,^[6] stated that Cell blocks improved the overall diagnosis and reduced the false negative results.

DISCUSSION: The thyroid gland is a dynamic organ of our body. Thyroid enlargement is a common clinical problem faced by many people with thyroid disorders. Though it is seen that colloid goiter is the most common disorder of the thyroid gland, it is vital to distinguish the various types of thyroid nodules, as this will aid in deciding the further line of treatment. However the ratio of carcinoma of the thyroid gland to benign enlargement is much less (1: 10),^[13,14] moreover, most thyroid

ORIGINAL ARTICLE

carcinomas are indolent permitting 90% survival at 20 years. So, it is important to identify patients that require surgery and others that do not require surgery and thereby can be treated by drugs.

For the proper diagnosis of the exact disease proper clinical findings, isotope scintigraphy, ultrasonography is required besides FNAC. FNAC has its own limitations and drawbacks, whereas the other requires sophisticated and expensive equipment and expertise technical skill. Moreover, these facilities are available in limited centres which are not within the affordable range of every patient in our country.

The cell block technique has been used for more than a century. The first report was made by Bahrenburg in 1896.^[15]

Cell block alone is superior to direct smears even for haemorrhagic thyroid FNAs. It shows increased diagnostic efficacy and slide reduction and obviates repeat FNAs.^[16]

In the present study, cell block study was done on a total of 90 cases diagnosed clinically with thyroid enlargement. All the cases were analyzed and correlated with FNAC. Out of these 90 cases, histopathological results were available for 47 cases. Thus, these 47 cases were included in the statistical analysis, as histopathological diagnosis was taken as the gold standard. The cases where histopathological examination could not be correlated, they were followed up by clinical, haematological and radiological work up.

Aspirates with insufficient cellularity (i.e. less than 5-6 groups of follicular epithelial cells with 10 or more cells per group) as we took the adequacy assessment protocol of Goellner et al.,^[17] or poor quality smear were considered “unsatisfactory” cell block negative for follicular cells.

In our study the cytological findings were categorized as Neoplastic, Non-Neoplastic and Non-diagnostic. Niria Sanchez et al.,^[18] in their study on diagnostic utility of cell blocks categorized their study in the same manner. Non-Neoplastic lesions included colloid goiter, adenomatous goiter, multi nodular goiter, thyroid cysts and Hashimoto’s thyroiditis, while in Neoplastic category we found the cases of Follicular Adenoma, Follicular Neoplasm, Papillary carcinoma and Anaplastic carcinoma. Cytologically, among the non-neoplastic lesions, colloid goiter was the commonest lesion (74.44%) followed by adenomatous goiter (5.56%), thyroid cyst (2.22%), Hashimoto’s Thyroiditis (1.11%) In the neoplastic cases, the most common was follicular neoplasm (10%) followed by papillary carcinoma (3.33%) and anaplastic carcinoma (1.11%) and Non –diagnostic cases were 2.22% as cellular material was obscured by necrotic and hemorrhagic elements.

Cell Block Findings: In the present study, Non-neoplastic lesions were 76.67% while the neoplastic lesions were 23.33% and no Non diagnostic cases. Among the Non-Neoplastic lesions Colloid goiter was the commonest 64.44% followed by adenomatous goiter (5.55%), thyroid cysts (2.22%), and equal cases of multi nodular goiter and Hashimoto’s thyroiditis (1.11%). In the Neoplastic cases, follicular adenoma was 11.11%, followed by Follicular neoplasm 7.77% (definite comment on follicular adenoma and carcinoma could not be made by cell morphology or micro architecture), papillary carcinoma 4.44% followed by medullary and anaplastic carcinoma 1.11% each. There were no cases in the Non-Diagnostic category. Ten (10) number of cases were diagnosed as follicular adenoma instead of colloid goiter (As diagnosed by FNAC) which correlated with subsequent histological findings. Another case of follicular neoplasm diagnosed by FNAC, was subsequently diagnosed as medullary carcinoma in cell block study which correlated with histological findings. Overall sensitivity was found to be higher than FNAC. Cell blocks provided more additional information like we could appreciate better cytological details in cell blocks as cases like papillary

ORIGINAL ARTICLE

carcinoma where Psammoma bodies [Fig-10], Orphan Annie eye nucleus and papillary structures could be well appreciated which cannot be visualized in FNAC, so Cell Blocks were more contributory. In a study by Basnet et al.,^[11] stated that Cell Blocks were more contributory in diagnosis than that of Direct smears. Rajib et al.,^[12] and Kathrine et al.^[19] also stated that Cell Blocks provide additional valuable information in most cases. However, a case diagnosed both by FNAC and by cell block study as follicular neoplasm was diagnosed to be follicular carcinoma histologically as proper capsular and vascular invasion could not be visualized cytologically which were evident on histopathological examination.

Our series showed 2 (two) cases of false positive results, both the cases were diagnosed as follicular neoplasm by cell block as well as by FNAC Histopathologically, 1 case proved to be adenomatoid goiter and the other was a thyroid cyst. Consistency of cell blocks as compared to Histopathological results was found to be 93.75% in Non-neoplastic cases and 82.36% in neoplastic lesions.

Renshaw et al.,^[20] found a significant gray zone among experts in the distinction between micro follicular and macro follicular grouping on cytology preparations. One of the gray zones relates to the problem of disaggregated follicular cells artificially piled on top of each other in cellular Smears. Cellblocks can often allow assessment of morphologic features of truly adjacent follicles. Thus we can conclude from the present study that Cell block technique showed to be highly effective with high sensitivity and specificity and could be utilized as a cost effective diagnostic tool in the armamentarium of diagnostic work up in the patients with thyroid lesions.

REFERENCES:

1. Unnikrishan AG, Menon UV. Thyroid disorders in India: An epidemiological perspective. *Indian J EndocrMetab.* 2011; 15; 78–81.
2. Richardson HL, Koss LG, Simon TR, An evaluation of the concomitant use of cytological and histocytological technique in the recognition of cancer in exfoliated material from various sources *Cancer.* 1955; 8: 948–950.
3. Lia K, Dodge R, Glasgow BJ, Layfield LJ. Fine needle aspiration. Comparison of smear, cytospin and cell block preparations in diagnostic and cost effectiveness. *Diagcytopathol* 1998; 19; 70–74.
4. Keyhami Rofaga S, O'Toole RV, Leming MF, Role of the cell block in fine needle aspiration *ActaCytolo.* 1984; 28: 630–631.
5. The techniques of FNA cytology In Svante R.orell, Gregory F, Max Walters (Eds) *Manual and atlas of fine needle aspiration cytology* 3rd Edition Churcill Livingstone.2001; Pg 16.
6. Nathan NA, Narayan E, Smith MM, Hou MJ. Cell block cytology. Improved preparation and its efficacy in diagnostic cytology. *Am J ClinPathol.* 2000; 114, 599–606.
7. Leuny SW, Bedard YC. Methods in pathology: sing miniblock technique for cytology *Mod. Pathol* 1993 6: 630–632.
8. Wojcik EM Selvagi SM. Comparison of increase and cell blocks in the fine needle aspiration diagnosis of recurrent. *Gynaecological, Acta Cytol* 1991; 35: 773–776.
9. Axe SR, Erozen YS, Erinmatinger SV. Fine needle aspirations of the lives: a comparison of and rinse preparations in the detection of com *AM J ClinPathol.* 1986; 86: 281–285.
10. Kern WM Haber M. Fine needle aspiration mini biopsies. *ActaCytol* 1986; 30: 403–408.

ORIGINAL ARTICLE

11. Basnet S, Talwar OP. Role of cell block preparation in neoplastic lesions. *Journal of Pathology of Nepal* (2012) Vol.2 – 272–276.
12. Rajib RC, Majid N, Rahman MR, Baqui MN, Shermin S. Role of “Cell block” in thyroid cytology a cross sectional study. *JAFMC Bangladesh*, Vol. 8, No 1: 30–33, 2012.
13. Wojcik EM Selvagi SM. Comparison of increase and cell blocks in the fine needle aspiration diagnosis of recurrent. *Gynaecological, Acta Cytol* 1991; 35: 773–776.
14. Axe SR, Erozen YS, Erinmatinger SV. Fine needle aspirations of the livers: a comparison of and rinse preparations in the detection of com AM *J ClinPathol*. 1986; 86: 281–285.
15. Bahrenburg LPH. On the diagnostic result of the microscopical examination of the ascitic fluid in two cases of carcinoma involving the peritoneum. *Clemeland Med Gaz*. 1896; 11: 274–278.
16. QuiL, Crapanzano JP, Saqi A, Vidhun R, Vazquez MF. Cell block alone as an ideal preparatory method for haemorrhagic thyroid nodule aspirates procured without onsite cytologists. *Acta cytol* 2008 Mar–Apr; 52(2) 139–44.
17. Gocllner JR: Gharib, H; Grant, CS; Johnson, DA. Fine needle aspirations cytology of the thyroid, 1980–1986. *ActaCytol*. 1987; 31. 587–590.
18. Niria Sanchez, Suzanne M. Selvaggi; *Diagnostic cytopathology*. Vol 34, Issue 2. Feb 2006.
19. Kathrine L, Richard D, Ben JG, Lester JL. Fine needle Aspiration Comparison of smear, Cytopsin and Cell Block preparation in diagnostic and cost effectiveness. *Diagn Cytopathol* 1998; 19: 70–74.
20. Renshaw AA, Wang E, Wilbur D et al. observer agreement on micro follicles in thyroid fine needle aspirates. *Archives of Pathology Laboratory Medicine* 2006; 130: 148–52.

AUTHORS:

1. Zarika Ahmed
2. Pranita Medhi
3. Debojit Das

PARTICULARS OF CONTRIBUTORS:

1. Demonstrator, Department of Pathology, Assam Medical College & Hospital, Dibrugarh, Assam.
2. Associate Professor, Department of Pathology, Assam Medical College & Hospital, Dibrugarh, Assam.

FINANCIAL OR OTHER

COMPETING INTERESTS: None

3. Professor, Department of ENT, Assam Medical College & Hospital, Dibrugarh, Assam.

NAME ADDRESS EMAIL ID OF THE CORRESPONDING AUTHOR:

Dr. Zarika Ahmed,
 Demonstrator,
 Department of Pathology,
 Assam Medical College & Hospital,
 Dibrugarh-786002, Assam.
 E-mail: zarika2007@rediffmail.com

Date of Submission: 04/09/2015.
 Date of Peer Review: 05/09/2015.
 Date of Acceptance: 15/09/2015.
 Date of Publishing: 21/09/2015.